

Ultrasound findings in cutaneous sarcoidosis

Ewa Dybiec¹, Aldona Pietrzak², Joanna Bartosińska², Robert Kieszko³, Jean Kanitakis⁴

¹Department of Pediatric Radiology, Medical University of Lublin, Lublin, Poland
Head of Department: Prof. Andrzej P. Wiczorek MD, PhD

²Department of Dermatology, Venereology and Pediatric Dermatology, Medical University of Lublin, Lublin, Poland
Head of Department: Prof. Grażyna Chodorowska MD, PhD

³Department of Pneumonology, Oncology and Allergology, Medical University of Lublin, Lublin, Poland
Head of Department: Prof. Janusz Milanowski MD, PhD

⁴Department of Dermatology, Ed. Herriot Hospital Group (Pav. R), Lyon, France
Head of Department: Prof. Michel Faure

Postep Derm Alergol 2015; XXXII, 1: 51–55

DOI: 10.5114/pdia.2014.40955

Abstract

The diagnosis of cutaneous sarcoidosis relies mainly on the patient's history, presence of characteristic skin lesions and histological examination that shows a granulomatous, non-necrotizing dermal infiltration. The aim of the study was to assess the ultrasonographic features of cutaneous lesions of sarcoidosis before and after treatment. A 38-year-old woman with systemic sarcoidosis and specific cutaneous lesions was treated with systemic steroids followed by hydroxychloroquine. Ultrasonographic examination of the cutaneous sarcoidosis lesions was performed with a Philips iU 22 and Siemens Acuson S 2000 device, with the use of linear 15 MHz and 17 MHz transducers. Histological examination of skin lesions showed characteristic, naked, non-necrotizing granulomas in the upper dermis. Ultrasound examination revealed well-demarcated, hypoechoic changes. Power-Doppler scan revealed increased vascularity within the lesions and the surrounding tissue. Clinical improvement of the skin lesions was confirmed by ultrasound examination, which showed a decrease in their size and normalization of dermal echogenicity and vascularity. Ultrasound examination can show cutaneous sarcoidosis lesions and their regression after appropriate treatment.

Key words: ultrasound, histology, sarcoidosis.

Introduction

Sarcoidosis is a systemic granulomatous disease of unknown origin with prevalence and manifestations depending on ethnic differences. The disease affects mainly the lungs and mediastinal lymph nodes, but the skin, eyes, parotid glands, heart, spleen, liver, cranial nerves and the central nervous system may also be involved. Cutaneous manifestations are present in about 25% of patients with sarcoidosis, the frequency of skin lesions being race-dependent [1, 2].

Skin lesions of sarcoidosis are either non-specific (e.g. erythema nodosum) or consist of specific granulomatous infiltrates manifesting clinically with maculopapules, papules of varying size, plaques, subcutaneous nodules, scars or erythematous infiltration (lupus pernio). Identification of individual skin lesions is of both diagnostic and

prognostic value. Cutaneous sarcoidosis, first described by Hutchinson in 1877, may precede systemic symptoms or represent a late manifestation of multi-organ disease. The diagnosis of cutaneous sarcoidosis relies on clinical findings, diascopy (revealing a pale yellowish-grey colour) and overall histopathological examination. Naked sarcoidal granulomas are the characteristic histological feature in cutaneous sarcoidosis, however, they may also be seen as a response to infectious agents, foreign bodies, immunodeficiency or lymphoproliferative disorders and drug-induced eruptions. Moreover, atypical histological findings such as the presence of necrosis, foreign material, periadnexal and perineural tropism of granulomas, interstitial distribution of granulomas, coexistence of lichenoid and granulomatous infiltrate, granulomatous vasculitis, and epidermal changes have been observed

Address for correspondence: Joanna Bartosińska MD, PhD, Department of Dermatology, Venereology and Pediatric Dermatology, Medical University of Lublin, 13 Radziwiłłowska St, 20-080 Lublin, Poland, phone: +48 602 724 298, e-mail: jbartosinski@gmail.com

Received: 21.08.2013, **accepted:** 25.11.2013.

in some cases [3, 4]. Recently, non-invasive imaging techniques (such as ultrasonography) have become available for the study of skin diseases. Ultrasounds, with the high-tech 17–20 MHz and higher ultrasound transducers, allow visualization of focal superficial skin changes within the dermis and subcutaneous tissue. This non-invasive technique fast-tracks diagnosing skin changes which so far have been detectable merely by palpation. Subcutaneous, painless and mobile nodules of this nature are also observed in the course of sarcoidosis [2, 5, 6].

We present here a patient with sarcoidosis, whose skin lesions were imaged with ultrasounds, both before and after successful treatment with antimalarials.

Case report

A 38-year-old woman consulted the outpatient clinic of the Department of Dermatology of the Lublin Medical University for asymptomatic eruptions on the back, buttocks, face and the right leg which had been noticed by the patient 6 months prior to consultation. The patient's medical history included right salivary-gland lithiasis and a uterine polyp; her family history was unremarkable. Physical examination showed firm, ill-defined, round or oval maculopapules, plaques and subcutaneous nodules. Some lesions were annular, with a raised border made of small nodules and a depressed centre. The overlying skin was red or yellowish-red with telangiectasia (Figure 1). Purplish-red papules were found over an old scar on the right knee. The skin tuberculin test was negative. His-

tological examination of a skin biopsy taken from the lesions confirmed the diagnosis of sarcoidosis manifesting with a well-defined dermal granulomatous infiltration with epithelioid and multinucleated giant cells but no necrosis (Figure 2). The patient underwent cryotherapy, which resulted in marked flattening and regression of the skin lesions. Chest X-rays and computed-tomography revealed bilateral hilar lymphadenopathy but no interstitial lesions. Videobronchoscopy showed mucosal hypervascularity, whereas a bronchial mucosal biopsy was inconclusive. Bronchoalveolar lavage could not be performed because of the flaccidity of the bronchial wall. The results of spirometry (forced vital capacity and expiratory volume) were normal.

In 2010, the patient developed dry cough, malaise, fatigue, fever, recurring and intense skin lesions, pain and burning sensation of the eyes. Chest X-rays and computed tomography revealed disseminated nodules in the lungs, which confirmed progression of the disease.

Laboratory tests revealed a slightly increased percentage of γ -globulins (19%, normal range: 6.4–16.2%) and slightly decreased values of alkaline phosphatase (33 U/l, normal range: 45–129 U/l). Complete blood cell count, routine biochemistry including electrolytes (sodium, potassium, calcium blood levels) as well as C-reactive protein and erythrocyte sedimentation rate were within normal limits. X-ray examination of the hands, abdominal ultrasound, electrocardiogram as well as ophthalmological examination did not reveal any abnormalities.

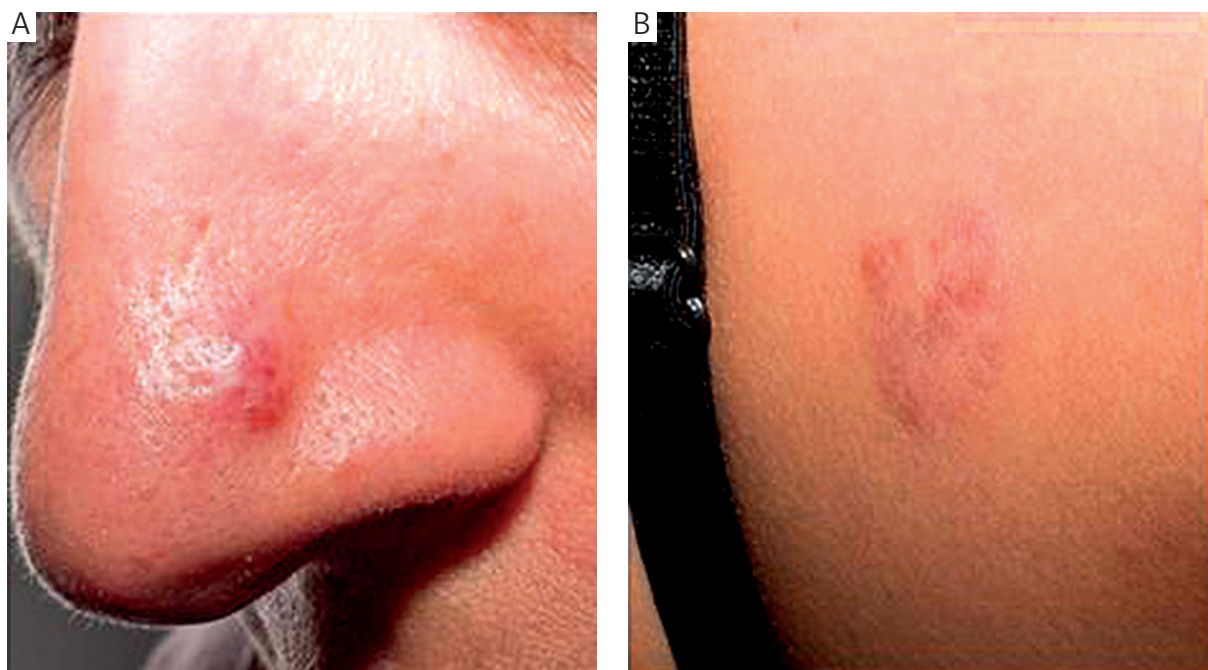


Figure 1. Ill-defined maculopapules on the nose (A) and on the back (B)

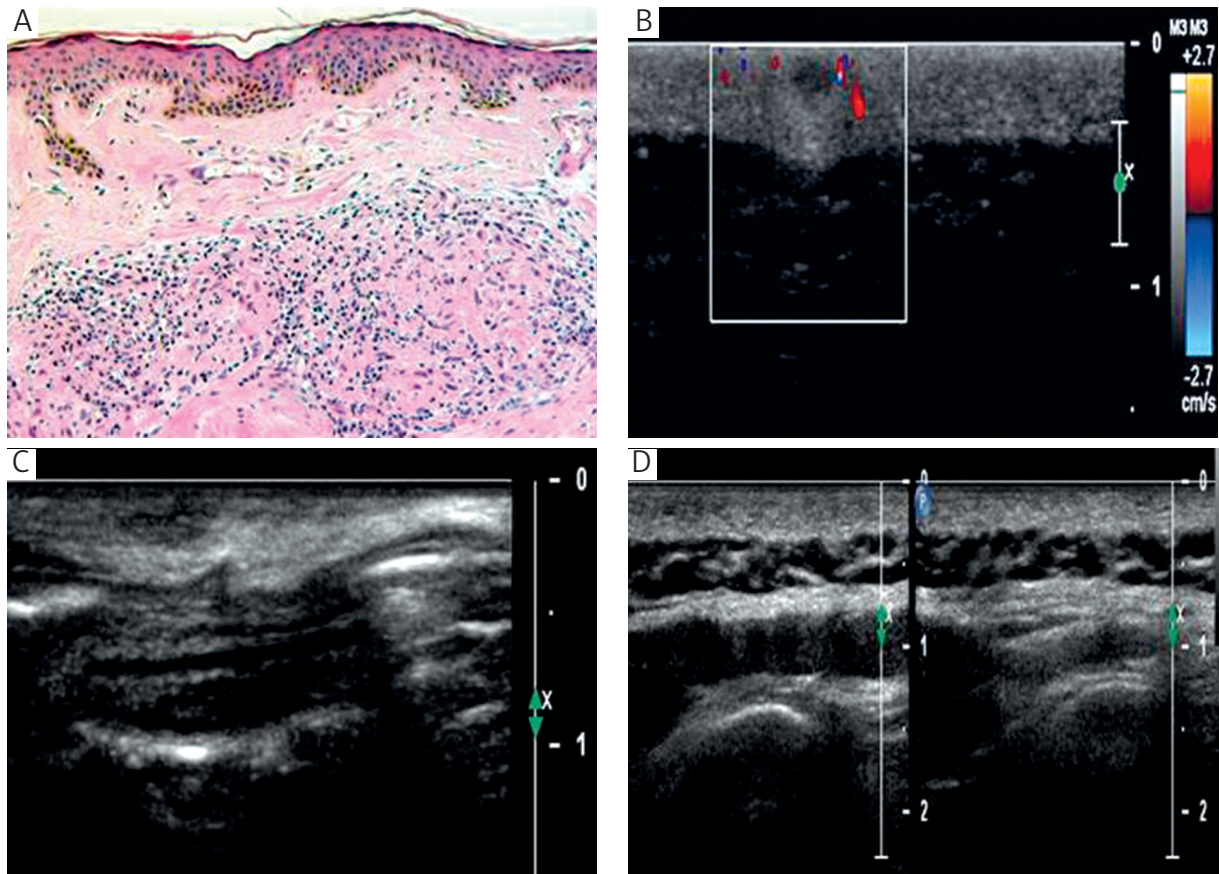


Figure 2. A – Histological examination of the skin lesion: naked, non-necrotizing dermal granulomas H + E stain 4.5 \times . Magnification should be 100 \times , instead of 4.5 \times . B – 17 MHz – linear-transducer ultrasound examination of the granuloma within the dermis. A well-demarcated, hypoechoic area is visible on ultrasound. On color Doppler visible blood flow signals around the skin change. C – 17 MHz – linear-transducer control ultrasound in the course of treatment. Increased echogenicity of the affected area and normalization of echogenicity in relation to the dermis. D – 17 MHz – linear-transducer control ultrasound after cessation of the treatment. Regression of the skin changes (on the left) and the image of contralateral normal-looking skin (on the right)

The patient underwent an initial skin ultrasound examination with the Philips iU 22 equipped with the linear 15 MHz and 17 MHz ultrasonic transducers as well as the Sonix ultrasound equipped with a 40 MHz ultrasonic transducer. B-mode imaging and color Doppler were also used. All palpable skin lesions, i.e. eight lesions on the back, one on the buttocks, one on the face and one spotted change on the right knee, were examined with regard to their position, echogenicity, size, borders and vascularization. Then, all the studied lesions were compared with the contralateral, normal skin. Ultrasound examination showed well-demarcated areas in the upper dermis with inhomogeneous hypo-echogenicity and surrounded by a small oedematous zone pressing down on the adjacent dermis and subcutaneous tissue (“a mass effect”). They measured up to 6 mm in longitudinal cross-section and up to 3 mm in transverse cross-section. Power color Doppler scan revealed increased vascularity within the lesions and in the surrounding dermis (Figure 2).

Because of systemic symptoms and the presence of disfiguring skin lesions, the patient was given treatment with oral prednisone (35 mg/day). During therapy she complained of nausea, diarrhea and gastric pain, suggestive of corticosteroid intolerance. In December 2011, treatment with the antimalarial drug hydroxychloroquine (Plaquenil®) was introduced (400 mg/day), initially for 5 days a week, then after 2 months, for 7 days a week. This resulted in flattening and regression of the skin lesions and clinical improvement (relief of cough, fatigue and fever). Spirometry remained normal. All the pretreatment nodular infiltrations that were visible in pulmonary computed tomography (CT) scans disappeared.

During treatment, control ultrasound examination revealed gradually increasing echogenicity of the dermis which initially manifested with small areas of increased echogenicity within the investigated area (Figure 2). The demarcation of skin changes became less apparent. Both palpation and ultrasound examination performed after

clinical resolution of the nodules showed normalization of the skin changes. The use of the 40 MHz ultrasonic transducer, however, showed a slight decrease in the echogenicity of the dermis at the site of the previously observed focal changes.

Discussion

Sarcoidosis patients with a more insidious disease onset typically present cutaneous lesions at an early stage of the disease, and these changes are usually accompanied by other systemic manifestations. However, in almost one-third of sarcoidosis patients skin lesions are the only manifestation; in that case they may be the first hallmark of systemic disease as the majority of these patients develop the multi-systemic disease months to years later.

Considering the complex and insidious nature of sarcoidosis, an early diagnosis is of great importance since this increases the chances to harness the disease [2, 5, 6].

Ultrasonography is a recognized method for the non-invasive imaging of focal organ changes. The sensitivity of this ultrasonic method in the assessment of superficial focal changes is high, whereas its specificity needs further investigations.

Even though ultrasonography may be useful in confirming a previously recognized or suspected disease, it does not ensure a definitive diagnosis unless the presence of a specific disease is suggested by previously-performed diagnostic tests. Reports on the ultrasound-detected features of cutaneous sarcoidosis are scarce. In 2010, Balan *et al.* [7] reported hypoechogenic foci within the dermis in cutaneous sarcoidosis lesions. Our findings are in keeping with this report, showing fairly well-demarcated foci of inhomogeneously decreased echogenicity. Chen *et al.* [8] performed a 7–12 MHz – transducer grey scale ultrasound in a patient with subcutaneous sarcoidosis and found several hyper-echoic, plaque-like lesions with regular contours in the thickened subcutaneous tissue. The discrepancy of the results obtained by Balan *et al.* [7] and Chen *et al.* [8] may be explained by different echogenicity of the skin nodules at different stages of their development. It is plausible that at the onset of the disease the skin changes are hypoechogenic and they become hyper-echoic after appropriate efficacious treatment. The repair process seems to affect the echogenicity of the skin changes, however this contention awaits confirmation.

Our findings suggest that ultrasound examination is useful in monitoring the efficacy of sarcoidosis treatment. The clinical regression of the skin changes in our patient was associated with normalization of the echogenicity as well as reduction of vascularity. The appearance of small hyperechogenic areas within sarcoidosis nodules may be a result of the repair processes and fibrosis. Interestingly, Polańska *et al.* [9] have also demonstrated the usefulness of ultrasound with a 20 MHz linear probe in monitoring

the effects of the treatment of some dermatoses, including atopic dermatitis, cutaneous T-cell lymphoma, eosinophilic fasciitis, morphea, plaque psoriasis and cutaneous graft versus host disease. According to Polańska *et al.* [9], after finishing the treatment of the selected inflammatory skin diseases, an increase in echogenicity was observed, whereas, in the examined connective tissue diseases the treatment with the use of UVA1 resulted in reduction of the skin thickness and decrease of its echogenicity.

Isolated examples of granulomatous diseases have been reported in the literature. Foreign bodies, i.e. splinters (wood, thorns), fish hooks, pieces of glass and metal, usually appear on ultrasound as hyperechoic linear structures. Frequently, those foreign bodies are surrounded by the hypoechogenic tissue that corresponds to a secondary inflammatory granulomatous reaction [10]. In his review of imaging of bone and soft tissue masses in children, Navarro [11] imaged subcutaneous granuloma annulare as ill-defined hypoechogenic areas in the subcutaneous tissue. Floyd *et al.* [12] reported a granuloma annulare of the penis in a 7-year-old boy, whose ultrasound showed a hypoechogenic, avascular lump containing a small area of fibrotic scarring. Kreuter *et al.* [13] found that 20 MHz ultrasound scanner examination was helpful in detecting a significant increase in dermal density after fumaric acid ester treatment in necrobiosis lipoidica. Homogeneous, hyperechoic structures, sometimes without sharp borders, have been observed in lipomas and fibromas on an 8.5 MHz – transducer ultrasound [14].

Neoplasms and vascular malformations should also enter the differential diagnosis of skin nodules seen by ultrasound examination. Skin cancers, including basal- and squamous-cell carcinoma and melanoma, present as hypoechogenic solid lesions. During follow-up, skin cancers commonly show increasing vascularity due to their high angiogenic power which is imaged by ultrasound examination. However, in the early proliferative phase, vascular malformations tend to be hypoechogenic and hypervascular, but later their echogenicity may increase and their vascularity decrease. Therefore, ultrasound examination seems helpful in the assessment of the vascularisation of skin lesions, which may in turn help distinguish benign from malignant changes [15, 16].

Conclusions

Our observations suggest that ultrasound examination could be useful in the monitoring of the treatment and follow-up of sarcoidosis patients. It appears that ultrasonography may facilitate an objective assessment of the sarcoidosis skin lesions as well as individual modification of the doses in the applied treatment.

In order to better delineate the sensitivity and specificity of ultrasound in the diagnosis of cutaneous sarcoidosis, more sarcoidosis cases should certainly be studied in the future.

Acknowledgments

We would like to thank Prof. Dorota Krasowska for the consultation of our patient and Bartłomiej Wawrzycki MD, PhD for taking photos of the skin lesions.

This study was supported by grant No. 168 of the Medical University of Lublin.

Conflict of interest

The authors declare no conflict of interest.

References

1. Hunninghake GW, Costabel U, Ando M, et al. The joint statement of the American Thoracic Society (ATS), the European Respiratory Society (ERS) and the World Association of Sarcoidosis and Other Granulomatous Disorders (WASOG). *Am J Respir Crit Care Med* 1999; 160: 736-55.
2. Haimovic A, Sanchez M, Judson MA, Prystowsky S. Sarcoidosis: a comprehensive review and update for the dermatologist: part I. Cutaneous disease. *J Am Acad Dermatol* 2012; 66: 699.e1-18.
3. Ball NJ, Kho GT, Martinka M. The histologic spectrum of cutaneous sarcoidosis: a study of twenty-eight cases. *J Cutan Pathol* 2004; 31: 160-8.
4. Cardoso JC, Cravo M, Reis JP, Tellechea O. Cutaneous sarcoidosis: a histopathological study. *J Eur Acad Dermatol Venereol* 2009; 23: 678-82.
5. Mañá J, Marcoval J. Skin manifestations of sarcoidosis. *Presse Med* 2012; 41: e355-74.
6. Mañá J, Marcoval J, Graells J, et al. Cutaneous involvement in sarcoidosis. Relationship to systemic disease. *Arch Dermatol* 1997; 133: 882-8.
7. Balan A, Hoey ET, Sheerin F, et al. Multi-technique imaging of sarcoidosis. *Clin Radiol* 2010; 65: 750-60.
8. Chen HH, Chen YM, Lan HH, et al. Sonographic appearance of subcutaneous sarcoidosis. *J Ultras Med* 2009; 28: 813-6.
9. Polańska A, Dańczak-Pazdrowska A, Silny W, et al. High-frequency ultrasonography in monitoring the effects of treatment of selected dermatoses. *Postep Derm Alergol* 2011; 28: 255-60.
10. Halaas GW. Management of foreign bodies in the skin. *Am Fam Physician* 2007; 76: 683-8.
11. Navarro OM. Soft tissue masses in children. *Radiol Clin North Am* 2011; 49: 1235-59.
12. Floyd MS Jr, Kokai G, McAndrew HF. Granuloma annulare of the penis in a seven-year-old boy. *Scand J Urol Nephrol* 2011; 45: 77-9.
13. Kreuter A, Knierim C, Stücker M, et al. Fumaric acid esters in necrobiosis lipoidica: results of a prospective noncontrolled study. *Br J Dermatol* 2005; 153: 802-7.
14. Kuwano Y, Ishizaki K, Watanabe R, Nanko H. Efficacy of diagnostic ultrasonography of lipomas, epidermal cysts, and ganglions. *Arch Dermatol* 2009; 145: 761-4.
15. Paltiel HL, Burrows PF, Kozakewich HP, et al. Soft tissue vascular anomalies: utility of US for diagnosis. *Radiology* 2000; 214: 747-54.
16. Catalano O, Caraco C, Mozzillo N, Siani A. Locoregional spread of cutaneous melanoma: sonography findings. *AJR Am J Roentgenol* 2010; 194: 735-45.