

Severe Darier's disease patient with mutation of ATP2A2

Cheng-Rang Li¹, Yu Zhang¹, Wei-Xue Jia¹, Xue-Min Xiao¹, Ning-Yan Gu¹, Nan Sheng¹, Qiu-Xia Mao¹, Xu Yao^{1,2}

¹Institute of Dermatology, Chinese Academy of Medical Sciences (CAMS) & Peking Union Medical College (PUMC), Nanjing, Jiangsu, China

Head of Department: Prof. Baoxi Wang

²Jiangsu Key Laboratory of Molecular Biology for Skin Diseases and STIs, Nanjing, China

Head of Department: Prof. Baoxi Wang

Postep Derm Alergol 2014; XXXI, 5: 338–340

DOI: 10.5114/pdia.2014.44030

Darier's disease (DD, OMIM 124200) is an autosomal dominant genodermatosis [1, 2] characterized by warty papules and plaques in seborrheic areas, such as the central trunk, flexures, scalp and forehead. The palms and soles show punctuate keratoses, and nail involvement includes subungual hyperkeratosis, fragility and triangular nicking of the free edges. Heat and sweating may exacerbate the disease [3]. Acrokeratosis verruciformis of Hopf (AKV, OMIM 101900) is a localized disorder of keratinization affecting the distal extremities, and the dorsa of the hands are affected first and most conspicuously. Recently, more and more articles have maintained that DD and AKV are variable expressions of the same disease. Genetic studies found that both diseases have the same defective gene, the ATP2A2 gene, encoding the sarco(endo)plasmic reticulum Ca²⁺-ATPase2 pump (SERCA2). In this study, we report a severe DD patient who had warty lesions on the dorsa of the hands resembling AKV.

A 37-year-old Chinese man presented with a 26 years' history of the skin lesion. He was born at full term and the neonatal period was uneventful. He developed discrete, keratotic papules on the face at the age of 11. The keratotic papules gradually increased and involved the trunk and extremities. The lesion became prominent in summer, while fainter in winter. His parents were asymptomatic. Physical examination demonstrated that the patient had normal intellectual ability, without any neuropsychiatric disorder or behavior problems. Skin-colored, yellow or yellow-brown, harsh, firm, greasy papules were widely distributed on the body (Figure 1 A). Some scattered lesions expanded and merged into warty papules and plaques. It was interesting that verruca-like lesions were noted on patient's dorsum aspects of the hands, which were similar with AKV (Figure 1 B). Punctuate keratoses were seen on the palms and soles. The nails were normal. And no abnormal manifestations were detected in the oral cavity.

Biopsy was taken from the right forearm of the patient, and processed for routine histopathology and step sectioned consecutively. A well-developed basal layer with projections ("villi") was in the acantholytic cleft, and hyperkeratosis and parakeratosis with rounded grains and suprabasal corps ronds (Figure 1 C).

After written informed consent, according to a protocol previously approved by the local Helsinki Committee, was obtained from the patient, and the study was approved by the Institutional Ethical Review Boards of the Peking Union Medical College, we performed a mutation analysis of the ATP2A2 gene in our patient. DNA was extracted from peripheral blood leukocytes. Genomic DNA was amplified by polymerase chain reaction (PCR) using primers spanning the entire coding sequence and the intron-exon boundaries of the ATP2A2 gene as previously described [4].

The patient was found to carry a heterozygous missense c.1484C>T mutation in exon 12 of the ATP2A2 gene. The mutation leads to the substitution of serine (TCG) at position 495 to leucine (TTG), which was not found in the patient's healthy parents, neither in 100 unrelated control individuals (Figure 2 B) indicating that it does not represent common polymorphisms (Figure 2 A).

Darier's disease, also known as Darier-White disease and keratosis follicularis, is a progressive, autosomal dominant genodermatosis with peculiar keratinization of the epidermis mostly over seborrheic areas [1]. Our patient presented generalized keratotic papules with AKV-like lesions on dorsa of the hands. The relationship between AKV and Darier's disease remains controversial. The supports for links between these conditions include the clinical similarity between AKV and the acral warty lesions affecting 50% of patients with Darier disease, and few reports of families containing both individuals with AKV and individuals with Darier disease, as well as the same gene responsible for both diseases [2, 5]. Therefore,

Address for correspondence: Xu Yao, Institute of Dermatology, Chinese Academy of Medical Sciences (CAMS) & Peking Union Medical College (PUMC), 12 Jiang-Wang-Miao Street, 210042 Nanjing, China, phone: +86 25 85478124, fax: +86 25 85473613, e-mail: dryao_xu@126.com

Received: 23.01.2014, **accepted:** 6.06.2014.

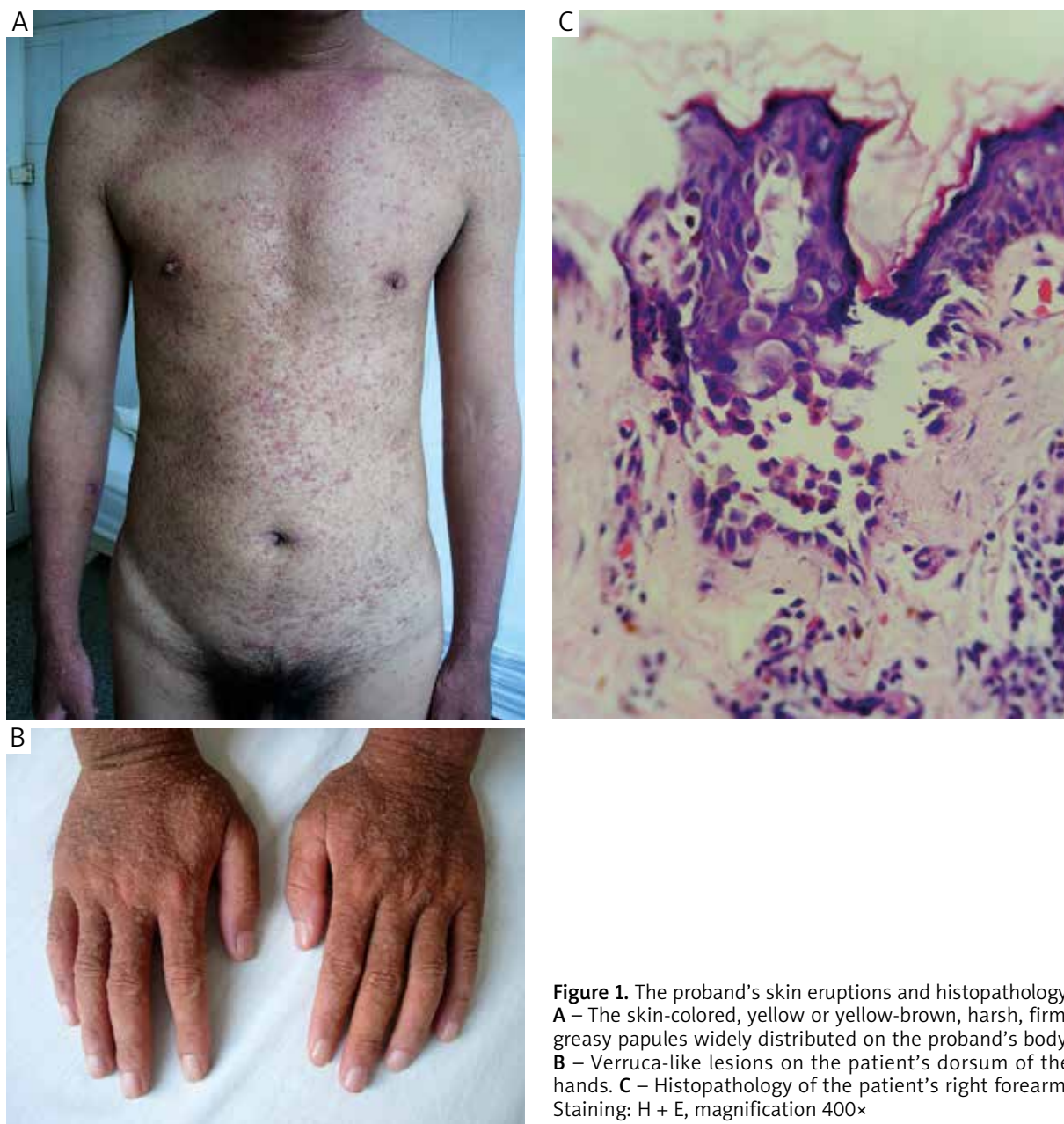

Figure 1. The proband's skin eruptions and histopathology. **A** – The skin-colored, yellow or yellow-brown, harsh, firm, greasy papules widely distributed on the proband's body. **B** – Verruca-like lesions on the patient's dorsum of the hands. **C** – Histopathology of the patient's right forearm. Staining: H + E, magnification 400×

more and more researchers agree that DD and AKV are variable expressions of the same disease, with the latter being a mild expression of the former. Whereas others maintain that AKV and DD are distinct entities on the basis of the difference in clinical, histological features and genetic locus [6–8].

The gene ATP2A2 encodes sarco(endo)plasmic reticulum Ca^{2+} -ATPase 2 (SERCA2), which catalyzes Ca^{2+} transport coupled with ATP hydrolysis and plays an essential role in maintaining Ca^{2+} homeostasis in the cytoplasm and endoplasmic reticulum lumen of cells [9, 10]. Searching for SERCA2 homologous proteins in GENBANK ([\[www.ncbi.nlm.nih.gov/GenBank\]\(http://www.ncbi.nlm.nih.gov/GenBank\)\), CDD \(Conserved Domain Database: <http://www.ncbi.nlm.nih.gov/Structure/cdd>\), and ProtoNet \(<http://www.protonet.cs.huji.ac.il>\), we found that Val474-Cys498, located in the ATP binding pocket on the nucleotide binding domain \(N domain\), is absolutely conserved in human, chimpanzees, dog, cattle, mouse, rat, fowl, and zebrafish. We speculate that Leu495 is required at very high concentrations of ATP and is important for the activity of the enzyme. In reported cases, the patient with F487S showed severe DD \[11\], and patients with M494L or M494I showed moderate to severe DD \[12\]. This may support the theory that N domain](http://</p>
</div>
<div data-bbox=)

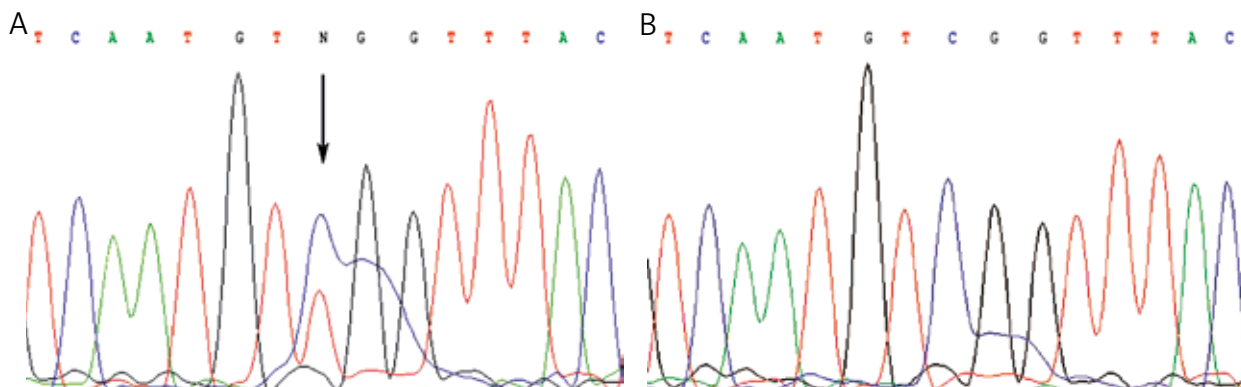


Figure 2. Mutation of ATP2A2 gene. **A** – The patient’s ATP2A2 genomic sequence coding base numbers 1477-1491, which showed c.1484C>T heterozygous mutation. **B** – The equivalent of ATP2A2 in a normal individual

is important for the activity of the enzyme and may be related with the phenotype of DD.

In summary, we have demonstrated a sporadic severe DD patient with AKV-like lesion on the dorsa of the hands. Based on previously published reports, we confirm that most mutations in that gene are private and the ATP2A2 gene mutation could occur in almost every motif without hotspots.

Acknowledgments

Cheng-Rang Li, Yu Zhang contributed equally to this work.

We are most grateful to the family of the patient with Darier’s disease and the healthy controls who so willingly participated and provided encouragement in this study. We thank Qi Li for helping us with the literature.

A statement of all funding sources that supported the work: Foundation of PUMC innovation team, Teaching and Research Fund Project of PUMC (Grant No. 2011zlgc0114, 303-05-8050).

References

1. Sakuntabhai A, Ruiz-Perez V, Carter S, et al. Mutations in ATP2A2, encoding a Ca²⁺ pump, cause Darier disease. *Nat Genet* 1999; 21: 271-7.
2. Dhitavat J, Macfarlane S, Dode L, et al. Acrokeratosis verruciformis of Hopf is caused by mutation in ATP2A2: evidence that it is allelic to Darier’s disease. *J Invest Dermatol* 2003; 120: 229-32.
3. Burge SM, Wilkinson JD. Darier-White disease: a review of the clinical features in 163 patients. *J Am Acad Dermatol* 1992; 27: 40-50.
4. Li CR, Cui PG, Jia H, et al. Identification of a novel mutation in a Chinese patient with mild Darier’s disease. *Int J Dermatol* 2010; 49: 1286-8.
5. Berk DR, Taube JM, Bruckner AL, et al. A sporadic patient with acrokeratosis verruciformis of Hopf and a novel ATP2A2 mutation. *Br J Dermatol* 2010; 163: 653-4.
6. Panja RK. Acrokeratosis verruciformis: (Hopf) – a clinical entity. *Br J Dermatol* 1977; 96: 643-52.
7. Chapman-Rolle L, DePadova-Elder SM, Ryan E, et al. Persistent flat-topped papules on the extremities. Acrokeratosis verruciformis (AKV) of Hopf. *Arch Dermatol* 1994; 130: 508-9, 511-12.
8. Wang PG, Gao M, Lin GS, et al. Genetic heterogeneity in acrokeratosis verruciformis of Hopf. *Clin Exp Dermatol* 2006; 31: 558-63.
9. Dode L, Andersen JP, Leslie N, et al. Dissection of the functional differences between sarco(endo)plasmic reticulum Ca²⁺-ATPase (SERCA) 1 and 2 isoforms and characterization of Darier disease (SERCA2) mutants by steady-state and transient kinetic analyses. *J Biol Chem* 2003; 278: 47877-89.
10. Miyauchi Y, Daiho T, Yamasaki K, et al. Comprehensive analysis of expression and function of 51 sarco(endo)plasmic reticulum Ca²⁺-ATPase mutants associated with Darier disease. *J Biol Chem* 2006; 281: 22882-95.
11. Ringpfeil F, Raus A, DiGiovanna JJ, et al. Darier disease – novel mutations in ATP2A2 and genotype-phenotype correlation. *Exp Dermatol* 2001; 10: 19-27.
12. Ren YQ, Gao M, Liang YH, et al. Five mutations of ATP2A2 gene in Chinese patients with Darier’s disease and a literature review of 86 cases reported in China. *Arch Dermatol Res* 2006; 298: 58-63.