

Giant naevus lipomatosus cutaneous superficialis on the buttock

Xinfeng Lu¹, Qian Zhang², Wenbo Bu², Fang Fang²

¹Department of Dermatology, Jingjiang People's Hospital, Jing Jiang, China

²Department of Dermatologic Surgery, Institute of Dermatology, Chinese Academy of Medical Science & Peking Union Medical College, Nanjing, China

Adv Dermatol Allergol 2021; XXXVIII (2): 333–334

DOI: <https://doi.org/10.5114/ada.2021.106213>

Naevus lipomatosus cutaneous superficialis (NLCS) is a rare idiopathic benign hamartomatous skin tumour characterized by mature ectopic dermal lipocytes with no associated systemic symptoms. It was first described by Hoffman and Zurhelle in 1921 [1] and is now classified into 2 clinical subtypes: classical (multiple) and solitary. The classical form usually presents in adolescence and consists of grouped, fleshy, skin-coloured to yellow papules and nodules that coalesce into plaques and are often located on the lower trunk, buttocks, or thighs in a segmental distribution. The second variant presents in adulthood as a solitary papule or nodule anywhere on the skin, including unusual sites such as the sole [2], nose [3], and vulva [4]. Here, we report a rare case of classical giant NLCS on the right buttock with successful treatment by surgical excision. To date, reported cases of NLCS with positive treatment outcomes, as in the case presented herein, are rare.

A 19-year-old girl presented with a giant (17 × 25 cm in size), flesh-coloured, soft, nontender, rubbery, sessile, and cerebriform mass on the right buttock, which was attached with multiple comedones on the surface (Figure 1 A). The mass appeared 10 years prior and gradually increased in size. When she visited our hospital, the mass was so large that her appearance and movement had been obviously influenced. There were no symptoms due to the lesions. The patient was otherwise healthy, and there was no relevant family history. No therapies had been attempted previously. Serum triglyceride and cholesterol levels were normal. The lesions were completely removed by excisional surgery and the treatment site was covered with local advanced flaps. Histological examination of a diagnostic biopsy found normal epidermis and mature fat cell deposits in the superficial dermis (Figure 1 B). Based on the clinical and histopathological features, the diagnosis of naevus lipomatosus cutaneous superficialis (NLCS) was made.

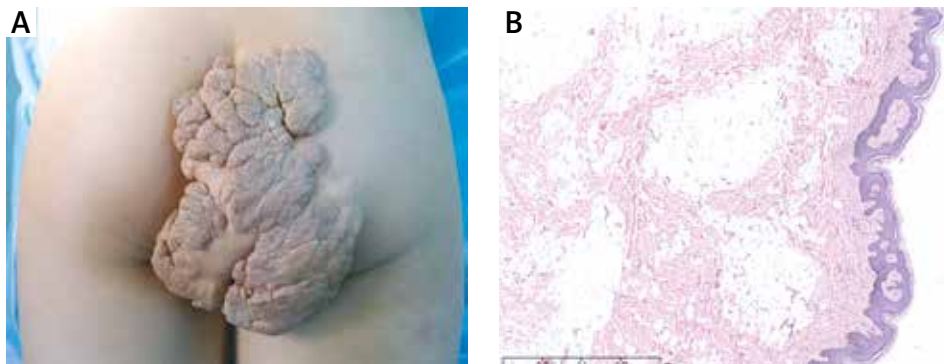


Figure 1. **A** – Extremely large (17 × 25 cm), flesh-coloured, soft, nontender, rubbery, sessile, and cerebriform mass on the right buttock with multiple comedones on the surface. **B** – Histopathological examination with mature fat cell deposits in the superficial dermis. H&E original magnification 40×

Address for correspondence: Qian Zhang, Wenbo Bu, Fang Fang, Institute of Dermatology, Chinese Academy of Medical Science & Peking Union Medical College, Nanjing, China, phone: +86 15150642234, fax: +86 25 85414477, e-mail: pumczq@163.com, buwenbo@163.com, fangfangjh@126.com

Received: 27.03.2018, **accepted:** 28.07.2019.

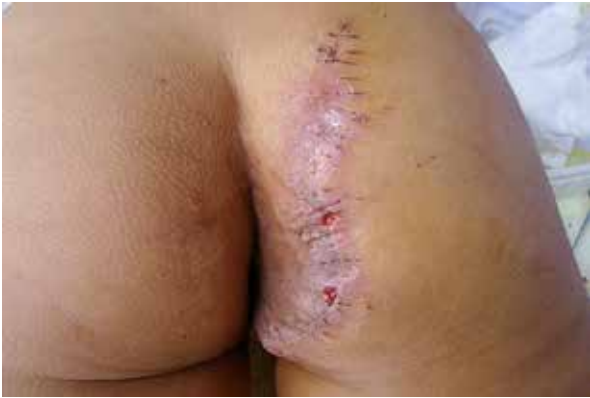

Figure 2. Postoperative appearance when stitches were removed 10 days after surgery

NLCS is a rare developmental anomaly characterized by isolated ectopic mature adipose tissue in the dermis [1]. Only a few cases have been reported in the literature worldwide. NLCS is usually present at birth but can arise anytime within the first 2 decades of life, with the main affected locations including the pelvic girdle, gluteal region, back, or abdomen [5]. The pathogenesis of NLCS is still unclear. Hoffman and Zurhelle postulated that fat deposition in the dermis is secondary to degenerative changes in the connective tissue [1]. Other theories include adipose metaplasia in the course of degenerative changes in dermal connective tissue, developmental displacement of adipose tissue, and possible adipocyte origin from the walls of dermal vessels. The peculiar histopathological finding is the presence of ectopic fat in the dermis, which may comprise 10–50% of the total lesion. NLCS differs from naevus sebaceous, neurofibroma, lymphangioma, focal dermal hypoplasia, cylindroma, trichoepithelioma, and angiolipoma. Therapy treatment is needed when the patient's appearance or quality of life is influenced. NLCS can be treated with surgery, cryotherapy, and CO₂ laser therapy [6]. If the lesions are not removed adequately by any method, recurrence is possible. We report a case of multiple NLCS (classical type) on the buttock, which was extremely large and rare. Due to adverse effects of the lesion on the patient's life and the extremely large size of the lesion, surgical excision was implemented. We excised the lesion completely only once, and the wound was reconstructed by local advanced flaps. The stitches were removed 10 days later with a satisfactory result (Figure 2). At the 24-month follow-up, the lesion had not relapsed. This case suggests that the treatment of NLCS is necessary because it can increase in size rapidly, although no malignant transformation has been described.

Acknowledgments

Wenbo Bu is supported by National Nature Science Foundation of China(81703142) and Qian Zhang is supported by the Fundamental Research Funds for the Central Universities (3332020062).

Conflict of interest

The authors declare no conflict of interest.

References

1. Dhamija A, Meherda A, D'Souza P, et al. Nevus lipomatosus cutaneous superficialis: an unusual presentation. *Indian Dermatol Online J* 2012; 3: 196-8.
2. Vano-Galvan S, Moreno C, Vano-Galvan E, et al. Solitary naevus lipomatosus cutaneous superficialis on the sole. *Eur J Dermatol* 2008; 18: 353-4.
3. Sáez Rodríguez M, Rodríguez-Martin M, Carnerero A, et al. Naevus lipomatosus cutaneous superficialis on the nose. *J Eur Acad Dermatol Venereol* 2005; 19: 751-2.
4. Nakashima K, Yoshida Y, Yamamoto O, et al. Nevus lipomatosus cutaneous superficialis of the vulva. *Eur J Dermatol* 2010; 20: 859-60.
5. Avhad G, Jerajari H. Nevus lipomatosus cutaneous superficialis. *Indian Dermatol Online J* 2013; 4: 376-7.
6. Fatah S, Ellis R, Seukeran DC, et al. Successful CO₂ laser treatment of naevus lipomatosus cutaneous superficialis. *Clin Exp Dermatol* 2010; 35: 559-60.